

Entrapment of the Extensor Indicis Proprius (EIP) tendon after Open Reduction and Internal Fixation (ORIF) of Distal Ulna Fracture



Shao-Min Shi, M.D. , Steven I. Grindel, M.D.
Department of Orthopaedic Surgery, Medical College of Wisconsin

Introduction

- ORIF of the distal ulna is a common procedure for fracture treatment as well as bone shortening.
- The EIP muscle arises from the posterior and radial surface of the distal third of the ulna and the adjacent interosseous membrane (Fig.1). The muscle may be damaged or compressed by a fixation plate during ORIF causing entrapment post-operatively.
- By literature review, there are no past reports of such complication.
- We report 3 cases of EIP entrapment after ulna ORIF and surgical results following release of the EIP insertion to address this.

Methods

- 3 cases of EIP entrapment after distal ulna ORIF were identified.
- Digit flexion and extension were full with the wrist placed in both neutral and extension for all subjects (Fig.3).
- However, with the wrist in flexion, index excursion was restricted, remaining in fixed extension in all 3 subjects (Fig 4).
- At surgical exploration, we confirmed our 3 cases to have entrapment of the EIP. In two of the cases the fixation plate was in an improper position, compressing the EIP muscle belly (Fig. 2), and in one case the EIP muscle was damaged by long screws.
- The EIP tendon was detached from the insertion and the plate was removed. Post-operatively a splint was applied for 4 weeks followed by physiotherapy.

Pre-op

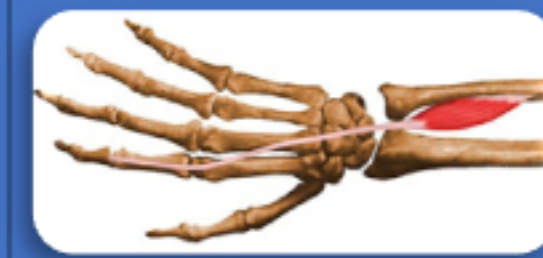

Fig. 1

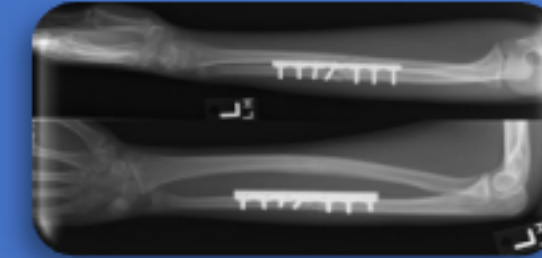


Fig. 2



Fig. 3

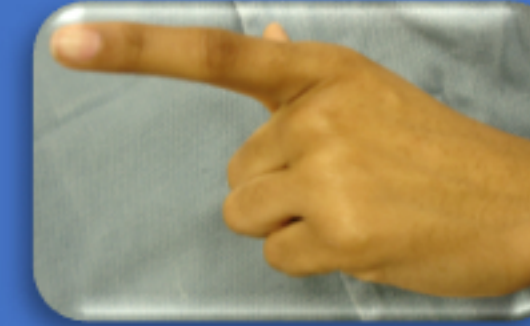

Fig. 4

Post-op



Fig. 5



Fig. 6

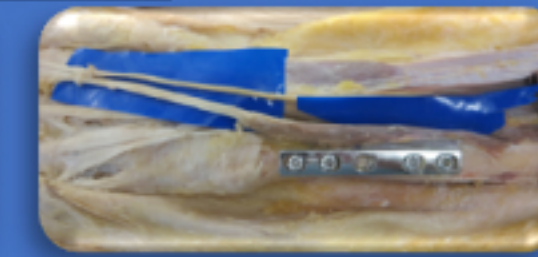
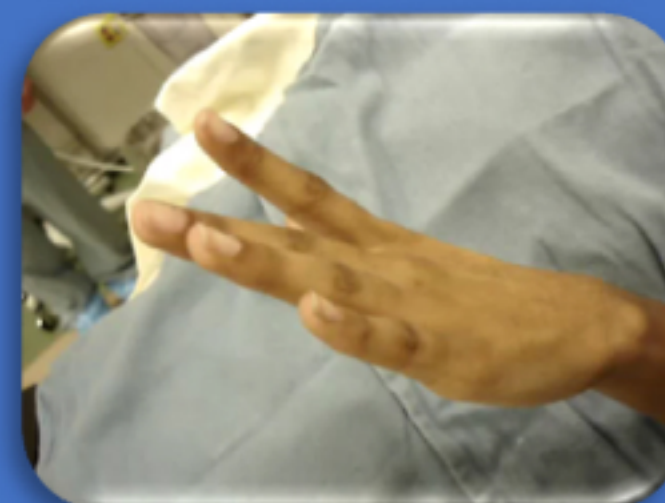

Fig. 7

Videos: pre & post-op



Results

- All 3 subjects achieved full index finger range of motion immediately post-operatively.
- Full digit motion was maintained in follow-up of 2 years post-operatively (Fig. 5, 6).

Conclusion

- Placement of the plate during ORIF of the distal ulna can contribute to entrapment of the EIP tendon.
- Detachment of the EIP insertion is an effective method to eliminate the entrapment.
- Utilizing cadaver dissection, we suggest that the posterior and ulnar surface is a proper place for the fixation plate to reduce the risk of EIP entrapment (Fig. 7).