

# Hand complications following radial artery catheterization for cardiac angiography

Jamison A. Harvey, BSc<sup>1</sup>; Sarasa T. Kim, BSc<sup>1</sup>; Mollie Ireson, BS<sup>1</sup>; Scott Harmsen, MS<sup>2</sup>; Rajiv Gulati, MD, PhD<sup>3</sup>; Malcom Bell, MD<sup>3</sup>; Steven L. Moran, MD<sup>4</sup>  
<sup>1</sup>Mayo Clinic School of Medicine, <sup>2</sup>Department of Biomedical Statistics and Informatics, <sup>3</sup>Department of Cardiology, <sup>4</sup>Department of Plastic Surgery- Mayo Clinic, Rochester, MN

## Background

- The radial artery is increasingly becoming the vessel of choice for cannulation in coronary angiography and percutaneous coronary intervention (CPI).
- Radial artery cannulation imposes risks to the hand and upper extremity.

## Objective

- To determine the frequency and types of upper limb complications, including need for surgical intervention, following radial artery access for cardiac angiography.

## Methods

- A retrospective review of electronic medical records of 10,540 patients that underwent coronary angiography +/-PCI between 2009 and September 2016.
- Medical records were examined to find complications and treatment of complications.
- The Kaplan Meier method was used to estimate survival to a first complication and/or death. The Cox model was used to assess risk factors for complication and death.

## Results

- 79 complications (.84%) diagnosed within 60 days (Figure 1).
- Ten patients required operative intervention (Table 2)
- Complications were diagnosed on a median of 1 day (IQR 0,7) after the procedure.
- Women were at increase risk for a hand complication (p<0.0001, HR 2.4; 95% CI, 1.5-3.7).
- Diabetes, age, BMI, and catheter size were not associated with increased risk. .

## Table 1: Patient Characteristics

Characteristic	Value
Median Age	65.9 [IQR 57.8, 74.9]
Sex	Number (%)
Female	3320 (31.5)
Male	7220 (68.5)
Width of catheter	
5	2969 (28.2%)
6	7568 (71.8%)
Median BMI	30.4

Figure 1: Variety of complications

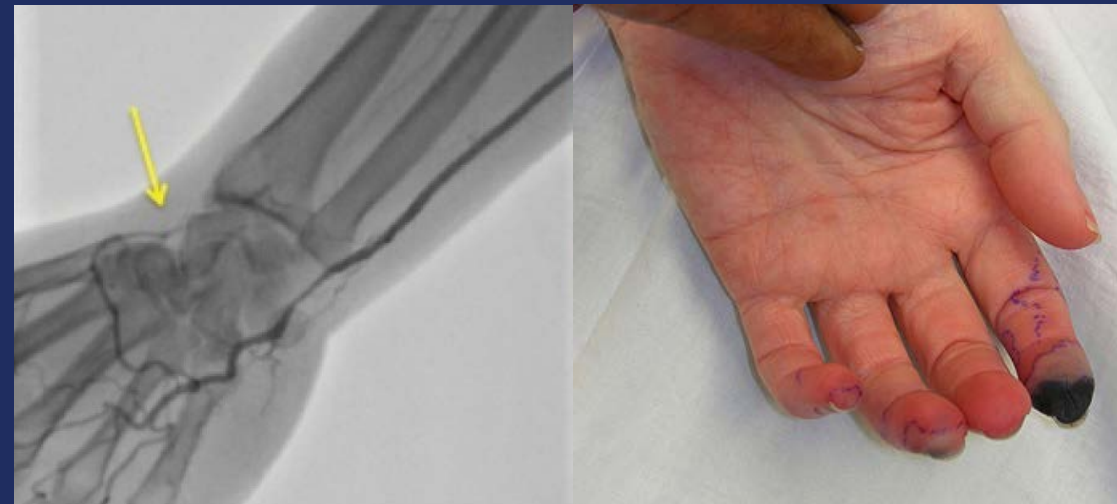
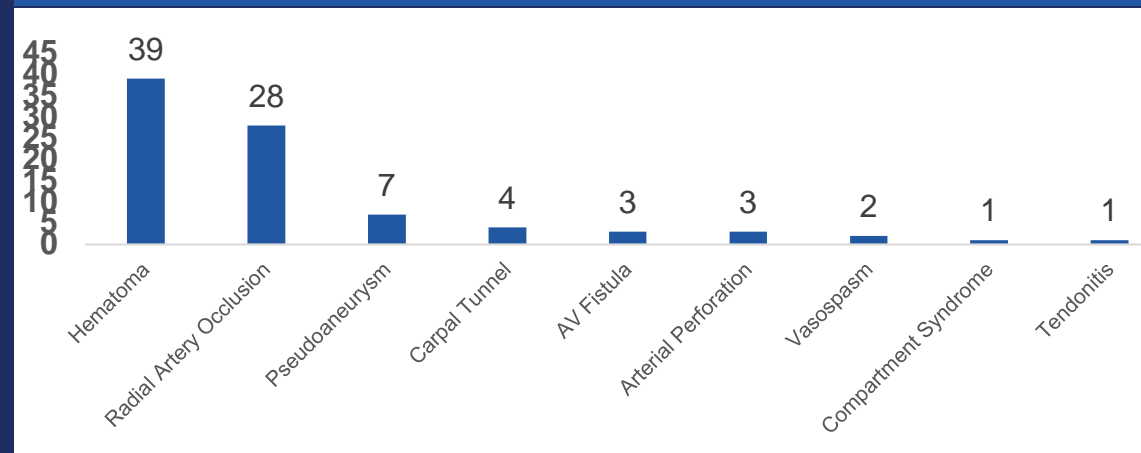


Table 2: Surgical Intervention

Complication	Number
<b>Radial Artery Occlusion</b>	
Conservative	14
Operative	4
Medical	9
<b>Pseudoaneurysm</b>	
Thrombin Injection	2
Operative	3
<b>Hematoma</b>	
Operative	1
Conservative	39
<b>Compartment Syndrome</b>	
Operative	1
<b>Arterial Perforation</b>	
Conservative	2
Protamine	1

## Conclusions

- Rate of hand complications following radial artery access for coronary angiography and PCI is very small
- However, patients should be monitored for complications such as occlusion, bleeding, compartment syndrome, AV fistula, and pseudoaneurysm