

Finger Dislocations and Ligament Injuries: **Finger MCP and PIP**

David G Dennison, MD
Mayo Clinic
AAHS 2015 Review Course

Disclosure – Research grant money received from DePuy
No material within this presentation is related to any industry support.

1. MCP Joint Anatomy

Condyloid joint – Multi-planar motion

MC head – cam shaped; base of P1 shallow concave

MCP immobilization should be in flexion to prevent loss of flexion from
tight collateral ligaments

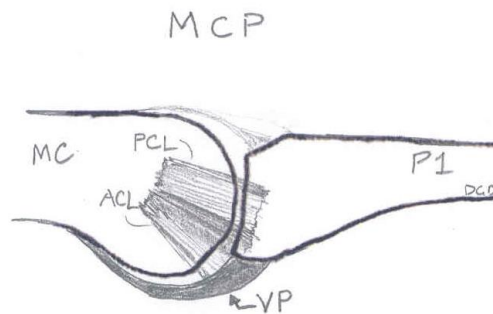
Volar plate

Weaker dorsal capsule

Ligaments

Proper collateral (PCL)

Accessory Collateral (ACL)



A1 pulley – directly volar to VP

Sagittal bands – attach to VP

2. MCP Dislocations, Fracture Dislocations and Ligament Injuries

Goals

- Identify injury immediately
- Don't make a reducible MCP joint irreducible by incorrect reduction
- Minimize or avoid complications of injury and surgery

Background

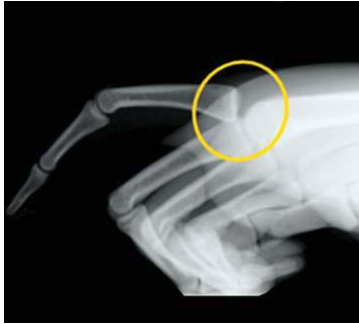- Fractures may be present in 50% of dislocations
- Complications - Stiffness, AVN, arthritis, pain

Definitions : Simple versus Complex Dislocations

- Simple – reducible with closed reduction
- Complex – requires operative reduction, usually due to trapped VP

Dorsal Dislocation (more common)

Mechanism – Hyperextension of MCP joint



J Am Acad Orthop Surg 2009;17:318-324

Simple MCP Dislocation

Volar plate torn but P1 remains in contact with MC head

No interposed tissue, hyperextended joint

Reduction (with anesthesia – local, sedation)

**No traction – this may trap the volar plate
and may convert a simple dislocation to
a complex dislocation**

Wrist and PIP flexed – relax flexor tendons

Slide P1 (dorsal to volar) and flex MCP

Post- reduction

Radiographs to confirm concentric reduction

Dorsal blocking splint is usually sufficient

Assess lateral stability in flexion

Rarely need to repair collateral ligament

(May occur with rotational injuries)

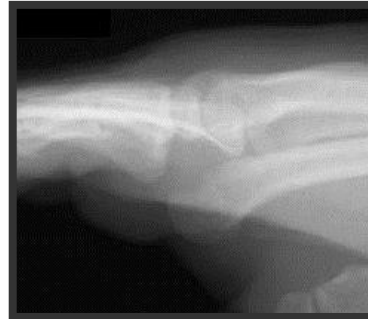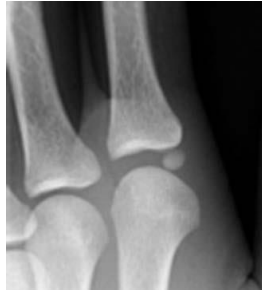Complex MCP Dislocation

Volar plate now interposed within MCP joint

P1 dorsal to MC, volar plate now dorsal to MC head

Parallel alignment of MC-P, volar skin dimpling

Sesamoid seen within the joint is pathognomonic



J Am Acad Orthop Surg 2009;17:318-324

MC head may also be trapped in volar palm structures:

FDP

Lumbrical

Natatory and superficial transverse MC ligament

This also brings the NV bundle closer to the skin

Biomechanical cadaver study indicates it is usually the volar plate that traps the joint and not the palmar “noose” described by Kaplan. (Afifi et al, JHS 2009 34A:1506-1511)

Open Reduction – Dorsal, Volar or combined

Dorsal Approach (e.g. Farabeuf)

Dorsal midline incision

Longitudinally divide the volar plate

Reduce the MCP joint

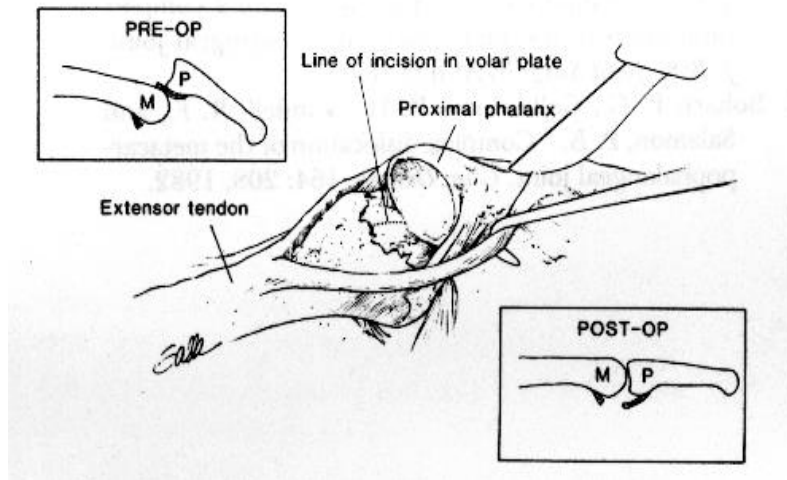
Inspect the articular surfaces

ORIF/Debride osteochondral fragments

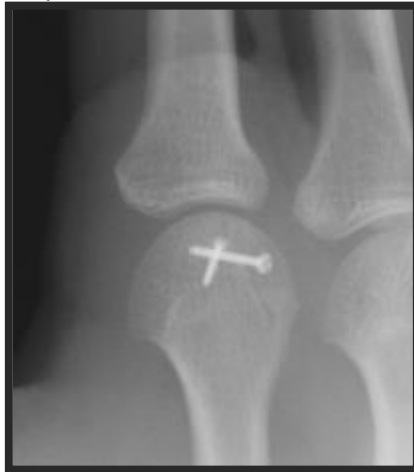Assess stability

Safe – away from displaced volar digital nerve

Cannot reach other volar structures



May et al. Plastic & Reconstructive Surgery 1988



Volar Approach (e.g Kaplan)

Allows access to other volar structures

Can see and divide the volar plate as well

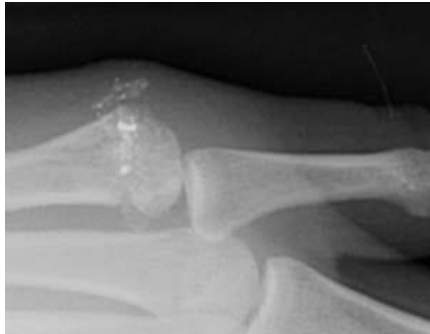Digital nerve is closer to skin and at risk

Cannot complete ORIF of osteochondral fx

Limited view of reduced articular surfaces

Volar MCP Dislocation (less common)

Mechanism - Hyperextension and hyperflexion described



J Am Acad Orthop Surg 2009;17:318-324

Simple Dislocation

Dorsal capsule torn and may be interposed in joint

Complex Dislocation

Other structures may interfere:

Extensor tendons

Distal volar plate/collateral ligaments

FDI

Closed reduction

Volar to Dorsal translation of P1 on the MC head

Begin with Flexed MCP and then Extend MCP

Open Reduction

Fewer reports of which direction is best for approach

Dorsal allows inspection of the joint, repair of capsule and
extraction of extensor tendon or ligament

Volar allows access to volar plate

3. Finger MCP Collateral Ligament Injuries

Avulsions – Origin or insertion

Avulsion fractures – Usually one volar “corner” of base of proximal phalanx

Displaced fx (intra-articular) may develop pseudo-arthritis or nonunion

Border digits common

Index and small finger

Physical Exam

Test in flexion of MCP for stability in radioulnar deviation

May find rotatory instability or subtle malrotation of fingers

Radiographs

3 views and Brewerton view may identify fractures

May see volar subluxation of P1

Treatment

Conservative

Partial tears or suitable endpoint to deviation stress
More likely to try conservative for LF and RF;
buddy taping is possible to adjacent finger

Operative

Large /displaced avulsion fractures
Open repair – ORIF
Percutaneous fixation
Arthroscopically assisted repair
Volar approach (Brunner over A1)
Also good for access for reduction/fixation

Unstable Ligament rupture/avulsion

Dorsal approach
Suture repair
Suture anchors work well
Many reports of good-excellent outcome with repair

4. Locked MCP joints

MCP joints can be locked in flexion, usually Index and Long
Often presents as “trigger finger” referral after stuck for some time.
Except – PIP has full motion

Two patient types:

1. Osteoarthritis (usually “older”)

Ligament caught over osteophyte; often Long finger
Osteophyte often visible by Brewerton view
Treatment - often open release
Dorsal Approach
Good visualization
May reduce ligament around osteophyte or débride osteophyte etc.

Volar Approach

Access to volar plate and volar ligament insertion
May be difficult to see dorsally due to flexed joint

2. Younger patients

Considered to be a soft tissue redundancy that traps
(usually) the radial collateral ligament of the index finger
Closed reduction advocated (with and without anesthesia)
Begin with hyperflexion, radial deviation, supination and
then extension

5. PIP Joint Anatomy

Bicondylar joint; 110 degrees of rotation 8-11 degrees of pro-supination

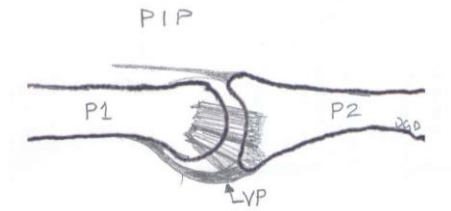
Significant stability from articular surfaces with flexion/grip/grasp

Ligaments (similar to MCP)

Proper Collateral

Accessory Collateral

Volar plate – strong insertion at lateral edges of P2



Transverse Retinacular ligament

Central slip of extensor mechanism

6. PIP Dislocations - Dorsal, Volar and Lateral

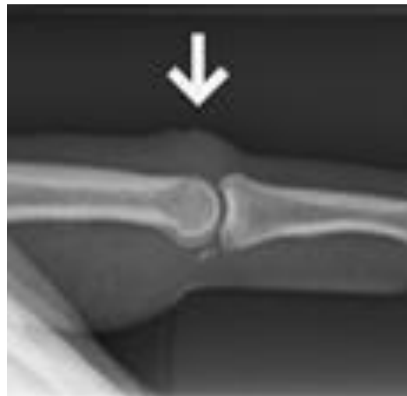Dorsal (P2 dorsal to P1)

Most common

Mechanism – usually Hyperextension, may have axial load too

Eaton described 3 types:

I Volar plate avulsion fracture off base of P1



Tx- buddy taping and early motion

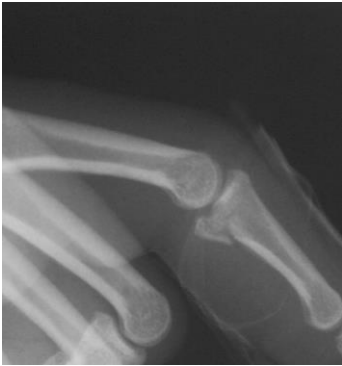II Dorsal dislocation

Tx – Digital block, traction and reduction

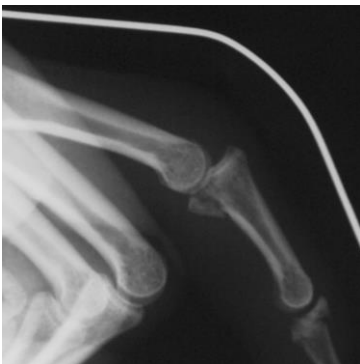Check stability

Radiographs to confirm concentric reduction

Extension block splinting and edema control
 Initiate flexion as soon as possible (pain/swelling)
 Progress towards full extension weekly
Make progress towards full extension to avoid the common complication of PIP flexion contracture



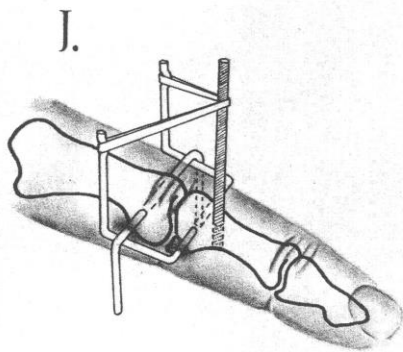
IIIA Dorsal Dislocation With P2 base fx (stable)
 Fracture <40% - still congruent articular joint dorsally
 Requires flexion (extension-block splinting) to prevent recurrent dislocation
 Historically – Schenck dynamic traction splint
 – large device, bulky



IIIB Dorsal Dislocation With P2 base fx (unstable)
Fracture >40% - joint dislocates, inadequate stability
Require surgical reduction and stabilization:
 No high powered studies to direct optimal treatment
 But, most less invasive treatments yield good results if concentric reduction with motion is achieved early.

Surgical options:

- Extension block pinning
- Trans-articular pinning
 - 3 weeks, < 40° (Newington)
- Force-Couple (e.g. Image: Agee, CORR 1987)**
- Dynamic Traction (e.g. Suzuki, Slade)
- Compass Hinge (e.g. Hotchkiss)
- ORIF with large fragments only (screws, cerclage)
 - Dorsal or Volar approach
 - Volar shotgun approach for cerclage or lag
- Volar plate arthroplasty
 - Volar approach
 - Resection of collateral ligaments
 - Advance distal VP into P2 base
 - Reliable results?
- Hemi Hamate reconstruction
 - Good early results
 - Technically more difficult/learning curve



P2 base Pilon Fractures – result from more axial load

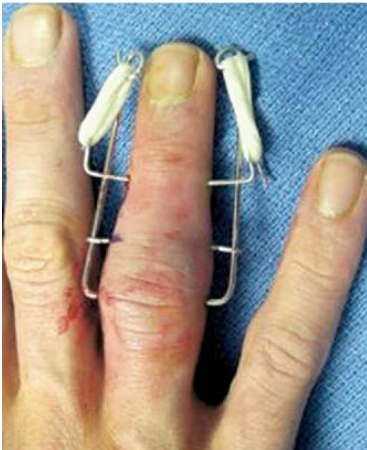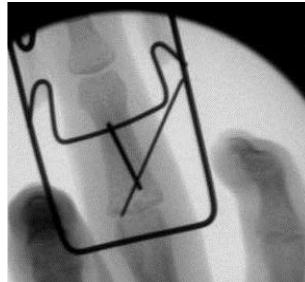
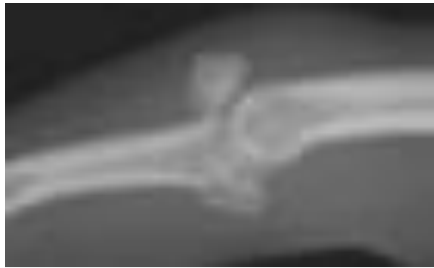Difficult injuries –

Complications include arthritis and stiffness

Soft tissue stiffness - major complication of open reduction

Need to maintain congruent surfaces and initiate motion

Results are equal or better for Dynamic traction compared to percutaneous fixation or ORIF



(Ruland et al. J Hand Surg 2008;33A:19–25.

Force-Couple is not applicable for pilon fractures as it does not distract the joint .

Volar Dislocations – Less common

Pure volar dislocations

Central slip injured with volar dislocation

Treatment : closed reduction

If stable → PIP extension splint 6 wks w/ active DIP motion

If unstable or with dorsal P2 fracture – may require repair

Dorsal P2 fx – ORIF, Perc or Extension block pinning

Volar rotatory dislocation

Mechanism - P2 spins on remaining intact ligament

Condyle ruptures between central slip and lateral band

Closed Reduction - requires rotation as well to reduce

MCP and PIP flexion assist with reduction of

condyle from soft tissue and then joint reduction

Open reduction may be required through a dorsal or
midaxial incision
Central slip/extensor mechanism inspected/repaired
Post reduction splinting – PIP extension with DIP motion

Lateral Dislocations

Mechanism – Deviation of joint with rupture of one collateral
ligament and volar plate

Treatment – Reduction, most by closed maneuver

Radiographs of joint to confirm concentric reduction

Look for joint incongruity = trapped soft tissue/bone

Rarely requires open reduction for trapped ligament

Midaxial or dorsal incision

Stiffness is much more common than instability

Ligament repair is rarely required

Perhaps with more chronic instability

Chronic or subacute PIP dislocations

May attempt open reduction if no arthritis

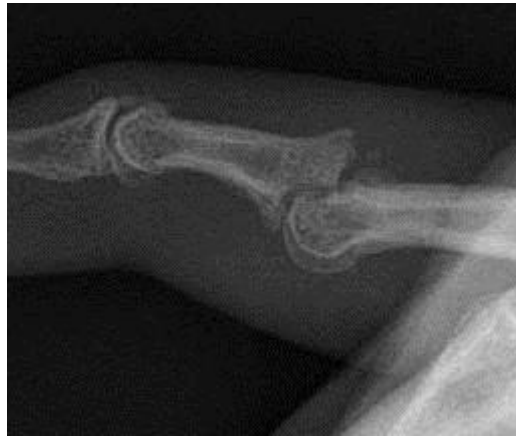May consider:

Volar Plate Arthroplasty

Hemi-hamate reconstruction

PIP fusion

PIP Arthroplasty?



References:

1. **Afendras G; Abramo A; Mrkonijic A; Geijer M; Kopylov P; and Tagil M:** Hemi-hamate osteochondral transplantation in the proximal interphalangeal dorsal fracture dislocations: A minimum 4 year follow-in in eight patients. *J Hand Surg [Er]*, 35: 261-341, 2010.
2. **Affi MA; Medoro A; Salas, C.; Taha M; and Cheema, T.:** A cadaver model that investigates irreducible metacarpophalangeal joint dislocation. . *J Hand Surg [AM]*, 34: 1506-1511, 2009.
3. **Agee JM:** Unstable fracture dislocations of the proximal interphalangeal joint. Treatment with the force couple splint. . *Clinical Orthopaedics and Related Research*, (214): 101-12, 1987.
4. **Ashmed D IV; Rothkopf DM; Walton RL; and JB, J.:** Treatment of hand injuries by external fixation. . *Journal of Hand Surgery*, 17(5): 956-964, 1992.
5. **Bain GI; Mehta JA; Heptinstall RJ; and Bria, M.:** Dynamic external fixation for injuries of the proximal interphalangeal joint. . *J Bone Joint Surg Am*, 80(6): 1014-9, 1998.
6. **Baldwin LW; Miller DL; Lockart LD; and EB, E.:** Metacarpophalangeal -joint dislocations of the fingers. . *J Bone Joint Surg Am*, 49: 1587-1590, 1967.
7. **Barry K; McGee H; and Curtin J:** Complex dislocation of the metacarpophalangeal joint of the index finger: A comparison of the surgical approaches. . *J Hand Surg [Br]*, 13: 466-468, 1988.
8. **Betz RR; Browne EZ; Perry GB; and EJ, R.:** The complex volar metacarpophalangeal-joint dislocation: A case report and review of the literature. *J Bone Joint Surg Am*, 64: 1374-1375, 1982.
9. **Bischoff R; Buechler U; De Roche R; and Jupiter J:** Clinical results of tension band fixation of avulsion fractures of the hand. *Journal of Hand Surgery* 19(6), 1994.
10. **Boden RA; Cavale N; and Fleming AN:** Kaplan's puckering sign in complex dorsal dislocation of the metacarpophalangeal joint of the index finger. *J Hand Surg [Br]*, 31: 576-577, 2006.
11. **Chadha M, and Dhal A:** Vulnerability of the radial digital neurovascular bundle of the index finger while using Kaplan's volar approach for irreducible dislocation of the second metacarpophalangeal joint. . *Injury*, 35: 1182-1184, 2004.
12. **Deitch MA; Kiefhaber TR; BR, C.; and Stern PJ:** Dorsal fracture dislocations of the proximal interphalangeal joint: Surgical complications and long-term results. . *Journal of Hand Surgery [Am]*, 24(5): 914-23, 1999.
13. **Delaere OP; suttor PM; Degolla R; Leach R; and Pieret PJ:** Early surgical treatment for collateral ligament rupture of metacarpophalangeal joints of the fingers. . *J Hand Surg [AM]*, 28(2): 209-15, 2003.
14. **Dionysian E, and Eaton RG:** The long-term outcome of volar plate arthroplasty of the proximal interphalangeal joint. *Journal of Hand Surgery*, 25(3): 429-37, 2000.

15. **Durham-Smith G, and McCarten GM:** Volar plate arthroplasty for closed proximal interphalangeal joint injuries. *Journal of Hand Surgery [Br]*, 17(4): 422-8, 1992.
16. **Eaton RG, and JW, L.:** Joint injuries and their sequelae. *Clin of Plastic Surgery*, 3(1): 85-98, 1976.
17. **Eaton RG, and Dray GJ:** Dislocations and ligament injuries in the digits, in Green DP (ed), Edited, 647-668, New York, NY, Churchill Livingstone, 1982.
18. **Eaton RG, and Malerich MM:** Volar plate arthroplasty of the proximal interphalangeal joint. A review of ten year's experience. *Journal of Hand Surgery [Am]*, 5(2): 260-8, 1980.
19. **Ellis SJ; Cheng R; Prokopis, P.; Chetboun A; Wolfe, S.; Athanasian EA; and Weiland AJ:** Treatment of proximal interphalangeal dorsal fracture-dislocation injuries with dynamic external fixation: a pins and rubber band system. *J Hand Surg [AM]*, 32(8), 2007.
20. **Flatt, A.:** Fracture-dislocation of an index metacarpophalangeal joint and an ulnar deviating force in the flexor tendons. *J Bone Joint Surg Am*, 48: 100-104, 1966.
21. **Gellman H; Massanelli GL; and WC, G.:** The effect of MCP position on strain of the collateral ligaments of the MCP joints in the hand during immobilization. . Edited by meeting, A. S. f. S. o. t. H. t. a., Seattle, 2000.
22. **Green DB, and Terry GC:** Complex dislocation of the metacarpophalangeal joint: Correlative pathological anatomy. *J Bone Joint Surg Am*, 55: 1480-1486, 1973.
23. **Hamilton SC; Stern, P.; Fassler PR; and Kiefhaber, T.:** Mini-screw fixation for the treatment of proximal interphalangeal joint dorsal fracture-dislocations. . *J Hand Surg [AM]*, 31: 1349-54, 2006.
24. **Hastings H II, and Ernst JM:** Dynamic external fixation for fractures of the proximal interphalangeal joint. . *Hand Clinic*, 9(4): 659-74, 1993.
25. **Hubbard LF:** Metacarpophalangeal dislocations. *Hand Clin*, 4: 39-44, 1988.
26. **Hunt JC; Watts HB; and Glasgow JD:** Dorsal dislocation of the metacarpophalangeal joint of the index finger with particular reference to open dislocation. *J Bone Joint Surg Am*, 49(8): 1572-1578, 1967.
27. **Ikeda M; Ishii T; Kobayaski Y; Mochida J; Saito I; and Oka Y:** Percutaneous pinning of the displaced volar plate avulsion fracture of the PIP joint. *Hand Surg*, 14: 113-9, 2009.
28. **Kang, L.; Rosen A; Potter HG; and Weiland, A.:** Rupture of the radial collateral ligament of the index metacarpophalangeal: diagnosis and surgical treatment. *J Hand Surg [AM]*, 32: 789-94, 2007.
29. **Klein DM, and Belsole RJ:** Percutaneous treatment of carpal, metacarpal, and phalangeal injuries. *Clinical Orthopaedics and Related Research*, 375: 116-25, 2000.
30. **Lee JY, and Teoh LC:** Dorsal Fracture dislocations of the proximal interphalangeal joint treated by open reduction and interfragmentary screw fixation: indications, approaches, and results. *J Hand Surg [Br]*, 31: 138-46, 2006.

31. **Lee, L.; Lee HM; Hou YT; Hung ST; Chen JK; and Shih JT:** Surgical outcome of the volar plate arthroplasty of the proximal interphalangeal joint using the mitek micro GII suture anchor. . *J Trauma*, 65: 116-22, 2008.
32. **Marck KW:** A tricky trigger finger: a patient iwht intermittent intrinsic locking of the metacarpophalangeal joint. . *Netherlands Journal of Surgury*, 39(5): 151-2, 1987.
33. **McElfresh EC, and Dobyns, J.:** Intra-articular metacarpal head fractures. . *Journal of Hand Surgery*, 8(4): 383-93, 1983.
34. **McElfresh EC; Dobyns, J.; and ET, O. B.:** Management of fracture-dislocation of the proximal interphalangeal joints by extension-block splinting. . *J Bone Joint Surg Am*, 54(8): 1705-11, 1972.
35. **McLaughlin HL:** Complex "locked" dislocation of the metacarpophalangeal joints. *J Trauma*, 5: 683-688, 1965.
36. **Minami A; An KN; 3rd, C. W.; Linscheid RL; and Chao EY:** Ligamentous structures of the metacarpophalangeal joint: a quantitative anatomic study. . *Journal of Orthpaedic Surgery and Research* 1: 361-8, 1984.
37. **Murphy AF, and Stark HH:** Closed dislocation of the metacarpophalangeal joint of the index finger. . *J Bone Joint Surg Am*, 49: 1579-1586, 1967.
38. **Newington DP; Davis TR; and Barton NJ:** The treatment of dorsal fracture-dislocation of the proximal interphalangeal joint by closed reduction and Kirschner wire fixation: A 16-year follow up. *Journal of Hand Surgery [Br]*, 26(6): 537-40, 2001.
39. **Patel MR, and Bassini L:** Irreducible palmar metacarpophalangeal joint dislocation due to junctura tendinum interposition: A case report and review of the literature. . *J Hand Surg [AM]*, 25: 166-172, 2000.
40. **Qvick L, and Wilhelm K:** Ligamental injuries of the MCP joints. *Z Plast Chir.* , 4(4): 260-5, 1984.
41. **Ruland RT; Hogan CJ; Cannon DL; and Slade JF:** Use of dynamic distraction external fixation for unstable fracture-dislocations of the proximal interphalangeal joint. *J Hand Surg [AM]*, 33(1): 19-25, 2008.
42. **Schenck RR:** The dynamic traction splint-fabrication and use. . Edited, American Society for Surgery of the Hand - Video Library, 1992.
43. **Schneck RR:** Dynamic traction and early passive movment for fractures of the proximal interphalangeal joint. . *Journal of Hand Surgery*, 11(6): 850-8, 1986.
44. **Slade JF; Baxamusa TH; and SW, W.:** External fixation of proximal interphalangeal joint fracture dislocations. . *Atlas of the Hand Clinics* 5(1): 1-29, 2000.
45. **Slade JF; Wolfe SW; and Gutow AP:** The treatment of unstable proximal interphalangeal joint fractures: How to apply and use a dynamic mini-external fixator. Edited, American Society for Surgery of the Hand - Video Library, 1996.
46. **Stern PJ, and Roman RJ:** Pilon fractures of the proximal interphalangeal joint. *Journal of Hand Surgery*, 16(5): 844-50, 1991.
47. **Tavin E, and Wray RC Jr:** Complex dislocation of the index metacarpophalangeal joint with entrapment of a sesamoid. . *Ann Plastic Surg*, 40: 59-61, 1998.

48. **Theumann NH et al.:** MR imaging of the metacarpophalangeal joints of the fingers: evaluation of 38 patients with chronic joint disability. . *Skeletal Radiology*, 34(4): 210-6, 2005.
49. **Vahey JW, and Wegner DA:** Effect of proximal interphalangeal fracture deformity on extensor tendon function. . *Journal of Hand Surgery*, 23(4): 673-81, 1998.
50. **Weiss AP, and Hastings H II:** Distal unicondylar fractures of the proximal phalanx. *Journal of Hand Surgery [Am]*, 18(4): 594-9, 1993.
51. **Wolfe SW, and LD, K.:** Intra-articular impaction fractures of the phalanges. . *Journal of Hand Surgery*, 20(2): 327-33, 1995.
52. **Yagi M; Yamanaka K; K, Y.; Sato N; and Inoue, A.:** Successful manual reduction of locked metacarpophalangeal joints in fingers. . *Journal of Bone and Joint Surgery*, 82: 366-371, 2000.
53. **Zemel NP:** Metacarpophalangeal joint injuries in fingers. *Hand Clin*, 8: 745-754, 1992.

Metacarpal and Phalangeal Fractures

David G Dennison, MD
Mayo Clinic
AAHS 2015 Review Course

Introduction

Metacarpal Fractures

- 30-40% of hand fractures, most common 5th MC neck (young male)

Phalangeal Fractures

- Feehan and Sheps:
 - 50% of hand fractures were phalangeal fractures
 - Male 2:1, especially in patients 15-40 y/o
 - Women are more likely to have hand fractures when >65 y/o

Treatment Principles and Background

- Fracture pattern and soft tissue injury varies with mechanism
- “Injury” films - assess the instability of the fracture
- Displaced fractures can be unstable even when the reduction looks good...
 - Initial deformity – best measure of instability.
- Outcome - proportional to the volume or severity of the injury
- Proximal phalanx, comminuted fractures and fractures with soft tissue injuries have worse outcomes
- Goals of operative reduction and fixation are to:
 - Provide sufficient stabilization
 - Minimize pain
 - Allow early motion
 - Minimize stiffness.
 - Limit dissection and soft tissue injury, keep hardware countersunk and not too close to the joint to minimize stiffness
- Facilitate motion by 4 weeks
- Postoperative evaluation, monitoring and therapy are **critical** in most cases

Fracture types in general

- Transverse, oblique, spiral, comminuted
 - Open, closed, contaminated, soft tissue injury, bone loss
 - Pediatric fractures
 - Thicker periosteum – more soft tissue stability

Metacarpal and Phalangeal Fractures :Functional Anatomy, Mechanics and Deformity (Excluding the thumb)

- Functional Anatomy
 - Radial side of the hand is rigid through the CMC
 - Ulnar side has more motion through the CMC joints
 - 20-30 degrees
 - Transverse arch to hand and carpus
- Mechanics and Deformity –Intrinsic, flexor and extensor muscle forces produce angular deformities
- Metacarpal Shaft
 - Intrinsic muscles produce an apex dorsal angulation; intermetacarpal ligament and interosseous muscles may limit shortening and malrotation
 - Rotation of 5 degrees = 1.5 cm of potential overlap
- Proximal Phalanx (P1)
 - Typically transverse fractures result in APEX VOLAR angulation as a result of the flexion force of the intrinsic muscle insertion on the base of the proximal phalanx and the extension force of the central slip across the PIP joint and distal portion of the proximal phalanx.
 - Extension lag - as much as 12 degrees for every 1 mm of shortening in the proximal phalanx
 - Oblique or spiral fractures may penetrate through soft tissue limiting closed reduction
- Middle Phalanx (P2)
 - Midshaft P2 fractures - variable presentation
 - Distal 1/3 fractures - apex volar as the FDS flexes the shaft of P2 and the extensor tendon extends the distal P2.
 - Proximal P2 fractures - result in apex dorsal deformity if proximal to the FDS insertion due to the extension from the central slip and flexion of the FDS
- Distal Phalanx (P3)
 - Few forces cross the tuft
 - Growth plate or base of P3 injuries may be unstable
 - some result in flexion (apex dorsal) deformity
 - e.g. Seymour fracture

Extra-articular Metacarpal and Phalangeal Fractures (excluding the thumb):

- Metacarpal Shaft
 - Acceptable alignment:
 - No clinical malrotation
 - Index and long – less than 10 degrees
 - Ring and small – less than 20 degrees
 - Shortening of 2mm = 7 degrees of extension lag,
 - may tolerate 3-4mm of shortening
 - Closed treatment –
 - Cast immobilization, MP flexed, IP free; duration 3-4 weeks
 - Frequent checks with X-rays
 - Operative treatment
 - Percutaneous Kwires (transverse, longitudinal, oblique) or transverse Kwire into adjacent intact MC shaft works well
 - IM nail –works well but less anatomic restoration of alignment
 - ORIF
 - Oblique or spiral fractures - lag screws or compress fracture and place a position screw
 - Plate with lag screw has increased rigidity
 - Transverse or comm. – plate dorsal or lateral
 - Tension band or intraosseous wiring also useful
 - Ex Fix – certain role with severe soft tissue injury, infection or loss of bone
 - Kwires with small systems (ie Hoffman phalangeal Ex fix)
 - Syringe with PMMA works well too
- Metacarpal Neck
 - Acceptable Alignment
 - No clinical malrotation
 - Angulation (not to exceed):
 - Index 10-15 degrees
 - Long 10-15 degrees
 - Ring 30-40 degrees
 - Small 40-50 (60+) degrees
 - Closed treatment
 - Reduction and cast application with a good three point mold
 - Historically by Jahss maneuver MP and PIP flexed..
 - The maneuver is good; the position for any period of time is bad!
 - I use a Beckenbaugh cast which is applied while the finger is in a finger trap with longitudinal traction and a cast with 3 pt mold is applied with the MP extended and the PIP free for about 3-4 weeks)
 - Close F/U

- Operative Treatment
 - Any wound that may communicate with the joint should be explored, débrided and irrigated; “fight bites” should not be missed.
 - Closed reduction and K wire fixation is usually acceptable
 - Open treatment for unstable, irreducible fractures
 - K wires, condylar blade plates, screws
- Metacarpal Base
 - Usually involves the 5th CMC
 - Look for injury at adjacent CMC
 - 30 degree Pronated AP and Lateral and/or CT
 - Closed treatment – nondisplaced : short arm cast
 - Displaced articular fractures or unstable CMC joint – deserve reduction and fixation, especially the 5th
- Phalangeal Shaft
 - General operative indications:
 - Displaced fractures with malrotation, angulation or excessive shortening
 - Guide: any malrotation, angulation > 10 degrees, shortening > 2 mm, apposition <50%
 - Distal phalanx with unstable fracture and nail matrix injury
 - Multiple fractures in the same hand, finger, extremity, or with polytrauma
 - Open fractures or replantation
 - Closed treatment includes casting/splinting with MP flexed and IP joints extended. Initiate motion as swelling subsides and callus and stability are present.
 - Frequent f/u
 - If you use less than a cast - you need a cooperative patient....
 - Operative Treatment
 - Closed reduction, perc pinning is mainstay, K wire reduction forcep is a valuable tool
 - CR/IF an option as well as ORIF
 - Plates : P1 – lateral better than dorsal regarding finger stiffness
 - P2 rarely plate..tendon scarring

Intra-articular Metacarpal and Phalangeal Fractures (excluding the thumb):

- Metacarpal Head
 - Good imaging is a necessity to make a good plan
 - Brewerton views
 - CT scan
 - Plan approach accordingly
 - Nondisplaced
 - Cast with MP flexed, close f/u
 - Displaced intra-articular fractures
 - ORIF (large fragments)
 - Arthroscopic assisted reduction and percutaneous fixation
 - Keep in mind - distal fractures have higher rate of osteonecrosis
- P1 Base
 - Unicondylar or avulsion fractures
 - Nondisplaced – cast with/ without buddy tape
 - Displaced fractures may lead to nonunion or pseudoarthrosis and instability
 - Closed versus open reduction
 - K wire fixation is satisfactory, screws and cannulated screws have been used with success
 - Unicondylar
 - Midaxial approach, dorsal for direct visualization of joint surface
 - Avulsion fracture (typically volar fragment):
 - Arthroscopic reduction and fixation reported
 - Volar approach through or around A1 pulley
 - Bicondylar fractures
 - Similar indications
 - Dorsal or lateral approach to MP joint
 - Blade plate (lateral) may be helpful
- P1 Head
 - Unicondylar or bicondylar
 - Nondisplaced – cast/splint intrinsic plus – WATCH CLOSELY
 - Displaced fractures
 - Attempt closed reduction with K wires and compression clamp, threaded K wires can help hold the reduction.
 - Articular reduction may require open reduction and screw, K wire, threaded K wire or tension band fixation. Bicondylar may benefit from blade plate.
 - Better joint motion when the hardware is kept away from the joint and periarticular tissues

- P2 Base
 - Volar plate avulsion fractures
 - Follows hyperextension or dorsal dislocation:
 - Goal - Maintain congruent reduction
 - Extension block splint with ACTIVE flexion
 - Good for smaller fragments with congruent joint
 - Force couple (eg: Agee)
 - Useful for reduction of joint subluxation
 - ORIF
 - Rarely– volar approach and ORIF with large fragment and coronal fracture plane
 - Volar plate arthroplasty
 - May help manage comminuted volar fragments and later reconstruction
 - Hamate osteochondral autograft
 - Reconstruct the volar lip
 - Central Slip Avulsion Fractures
 - Nondisplaced fractures – splint PIP in extension, mobilize DIP
 - Displaced fractures
 - Closed reduction, percutaneous fixation
 - Extension block pinning versus direct fixation of fragments
 - ORIF for large fragments
 - Pilon type
 - Difficult problem regardless of the method used to treat
 - Min/Nondisplaced
 - Early ROM, close F/U
 - May choose to unload the joint as well (see below)
 - Displaced
 - Dynamic Ex Fix with distraction close f/u and PIP ROM
 - Closed reduction and perc pins
 - Compass hinge
 - Schenk splint
 - Early ROM
 - Rare...ORIF
- Mallet Fracture
 - Closed treatment with DIP full time extension
 - For smaller fragments with a congruent joint
 - Check extension splint films for joint and fracture alignment
 - 6 weeks with ACTIVE PIP motion, then 6 weeks PM splint
 - Closed reduction, extension block pinning –
 - For large displaced fragments (40-60%) of joint
 - Joint subluxation
 - Rarely ORIF, higher complication rate

The Thumb: Metacarpal and Phalangeal Fractures

- Thumb
 - P1 and P2 fracture indications and treatment are similar to fingers
 - Metacarpal extra-articular shaft fractures
 - Tolerate 20-30 degrees of angulation
 - Slight malrotation may be acceptable due to motion at Thumb CMC joint
 - CR/PF when practical
 - ORIF for comminuted, displaced, unstable fractures
 - EPL/EPB interval for dorsal approach to Th MC
 - Plates, screws, Kwires, condylar blade plates and 2 mm locked plates are available for fixation
 - Intra-articular base of thumb metacarpal fractures
 - Need good imaging
 - Robert's view: (AP) of Thumb MC-Trapezial joint
 - Bennett Fracture – most common
 - APL pulls thumb MC proximal, volar oblique ligament intact and attaches to the remaining small volar bone fragment
 - Reduction requires traction, depression of the base of the metacarpal (extension) and pronation
 - K wires fixation may be from Th MC to Tzm and/or Index MC – does not have to pass through the small volar fragment as long as the fracture is reduced and stabilized
 - May be assisted by thumb CMC arthroscopy or open reduction
 - Rolando Fracture
 - T, Y or 3 part intra-articular fracture
 - CT for good visualization
 - Displaced fractures (>2mm?)
 - Open reduction/internal fixation
 - Dorsal approach
 - Wagner approach
 - K wire, screws, Ex Fix, Locked plate and condylar plate fixation
 - Bone graft

- Thumb MCP Ulnar collateral ligament injuries
 - Ulnar collateral ligament (most common)
 - Rupture
 1. Partial or complete
 - Physical exam
 - Test at 0 and 30 deg of MP flexion
 - Palpate for Stener lesion
 - Compare to opposite side for radial and ulnar deviation and endpoint
 - > 40 degrees suspicious for complete tear
 - Stress Xrays???
 - MRI
 - Evaluate for Stener lesion or complete tear and associated injuries (capsule, EPB, RCL)
 - Avulsion fracture
 1. Size
 2. Displacement, articular incongruity
 3. Nondisplaced – cast
 - Some controversy...verus
 4. Closed reduction and pinning with cast
 5. Open reduction, internal or perc fixation
 - Fractures and avulsions can occur together!

Techniques - Closed Reduction of Shaft Fractures:

- Relax the intrinsic with flexion of the MCP
- In general - Traction, accentuate the deformity and then reverse the deformity.
 - Irreducible fractures are usually due to interposed soft tissue
- Check clinical alignment and rotation.
 - Flexion and extension
 - Axial plane of the fingernails when the finger cannot be flexed.
- Buddy tape with the MCP flexed and IPs extended
 - Obtain films to evaluate reduction, splints may then be applied
- Close f/u (weekly) to evaluate for maintenance of the reduced position and to begin motion by 3-4 weeks.

Open Reduction: Approaches to the Metacarpals and Phalanges

Metacarpal

- Dorsal
 - Incision is standard although exposes tendons to scarring
- Lateral
 - Incision may be used for index and small finger – keeps implants and scar away from extensor tendons

Phalangeal

- Dorsal
 - Extensor tendon splitting
 - Advantage - good visualization
 - Disadvantage – direct scarring to the extensor tendon
 - PIP exposure for articular (especially unicondylar) fractures is through a central slip-lateral band splitting approach
- Lateral
 - Midaxial or midlateral incisions
 - Approach through, around, or with excision of part of the lateral band
 - Advantage – may minimize scar, allows access for condylar or fixed angle plate
 - Disadvantage – may be more difficult to visualize fracture and work through this window
- Volar
 - Brunner
 - Center at PIP flexion crease for access to PIP with retraction of flexor tendons
 - ORIF coronal volar lip fractures
 - Volar plate arthroplasty etc.

Implants or Fixation for Metacarpal and Phalangeal Fractures:

- Kirschner wires (K wires) – simple, available, cheap, versatile
 - Internal splint, minimal or no compression
 - Two crossed wires should not intersect at the fracture
 - Two wires required for rotational control
 - Stability is related to:
 - number of K wires
 - arrangement of wires relative to the fracture,
 - diameter of the K wires
 - Fracture must be reduced (and compressed) prior to pin fixation
 - K Wire perpendicular to the **fracture plane** best resists bending, torque and distraction with oblique/spiral fracture
 - K wire perpendicular to the **long axis of the bone** best resists longitudinal shortening in oblique/spiral fractures.
 - K wire reduction forcep is a valuable tool

- Stainless wire (26-28 Gauge)
 - 90:90 intraosseous wiring
 - tension band with K-wires
 - cerclage wire
- Screws
 - Provide compression
 - Modular/ headless/ cannulated
 - Strength proportional to minor diameter
 - lag screw – most compression perpendicular to the fracture plane
 - resists longitudinal force best when perpendicular to the long axis of the bone
- Plates
 - Bending strength proportional the cube of its thickness and inversely to the cube of the length.
 - Provide stability and allow early motion
 - Four cortices (2 bicortical screws) on each side of the fracture for phalangeal fractures is advisable
 - Allows compression with eccentric screw placement
 - Stainless or Titanium
 - Titanium may stress shield less
 - Condylar plates, T-plates, compression plates, H plates
 - Conventional screws
 - Small locked plates – fixed angle implant
 - Preserve periosteum, stable fixation especially with small or osteoporotic bone
 - Plates have been associated with complications in up to 36% of fractures
 - Stiffness, nonunion, plate prominence, infection and tendon rupture
 - However, those fractures with more stiffness were usually **open** phalangeal fractures; plate or injury?.
- Intramedullary (IM) nails, or rods, or K wires
 - Most well suited for transverse or short oblique fractures
- Bioabsorbable implants
 - Evolving role, no routine implants at this time
 - Plates, pins, screws
 - Similar dissection for application
- External fixation
 - Applied in midaxial or dorsal midline plane to minimize tendon scarring
 - dorsal midline may be best secondary location
 - Phalangeal fixators systems
 - Multiple K-wires with PMMA filled syringe

Putting it all together, some examples - Distal Phalanx

- Tuft: Most common, few deforming forces
 - Subungual hematoma:
 - >50% suggests nailbed laceration
 - Controversy – some literature shows no significant improvement with nail removal and repair (Roser 1999).
 - Displaced nail plates should be removed and the nailbed repaired with absorbable suture
 - Requires splint at DIP and MOTION at PIP
 - Sensory problems may persist; desensitization may help.
 - Fibrous union is common and usually asymptomatic
- Shaft: Transverse, Longitudinal, Comminuted – higher energy injuries : crush or saw
 - Open injuries or those with nail plate avulsion require irrigation and debridement, stabilization (K wire or nail plate) and nailbed repair with attention to the germinal and sterile matrices
 - Seymour fracture or displaced fractures with nail avulsion or displacement may require reduction and K wire fixation if the reduced nail plate does not provide enough stability.

Middle Phalanx Fractures

- Shaft
 - Transverse
 - IM or crossed K wires
 - Try to spare DIP and PIP joints and peri-articular soft tissue
 - Trans-articular for small distal middle phalanx neck fractures
 - Oblique/Spiral
 - Percutaneous reduction/compression with K wire reduction forcep
 - Multiple transverse K wires (perpendicular to fx and/or shaft)
 - May use threaded K wire to minimize gapping
 - Open or percutaneous lag screws
 - Comminuted/Segmental
 - K wires
 - Ex Fix
 - Multiple K wires
 - Transverse or oblique “fragment to fragment”

Proximal Phalanx Fractures

- Shaft
 - Transverse
 - IM or crossed K wires
 - Antegrade, retrograde and transarticular
 - MP should be flexed if wire goes across the joint
 - Oblique/Spiral
 - Percutaneous reduction and compression with K wire reduction forcep
 - Multiple transverse/oblique K wires
 - May use threaded K wire to minimize gapping
 - Open or Percutaneous reduction and fixation with lag screws
 - Lag screws alone are sufficient once the fracture plane is longer than twice the diameter
 - Short oblique/spiral – may require additional support: K wires or plate
 - Comminuted/Segmental
 - K wires
 - External fixator
 - Condylar blade plate - lateral approach
 - Dorsal plate – dorsal tendon splitting approach

Rehabilitation and Postoperative care

- Elevation and compression to minimize edema
- Mobilize other fingers and joints
- Splint to protect the finger or hand
- Cannot wait for radiographic obliteration of fracture planes for phalanx fractures, by 4 weeks active motion should begin in most cases

Pearls:

- Always examine the other hand before you start
- Mark the midaxial line prior to percutaneous fixation (wires placed above this are in a safe zone)
- K-wire reduction forcep is a great tool, needles can also help to direct wires and protect soft tissue.
- Oscillation feature on the K-wire driver can help minimize soft tissue injury.
- Minimize trauma to the tendons and soft tissue
- Make sure you move them...by 4 weeks
- Be satisfied with your reduction and fixation before you leave the OR
- Fracture pattern, soft tissue injury, and surgeon preference or experience must guide the surgical approach and choice of implant.

References

1. Agee J: Treatment principles for proximal and middle phalangeal fractures. *Orthop Clin N Am* 23:35, 1992
2. Al Qattan MM, Hashem F, Helmi A: Irreducible tuft fractures of the distal phalanx. *J Hand Surg* 28B:18, 2003
3. Al-Qattan MM: Juxta-epiphyseal fractures of the base of the proximal phalanx of the fingers in children and adolescents. *J Hand Surg* 27B:24, 2002
4. Belsky MR, Eaton RG, Lane LB: Closed reduction and internal fixation of proximal phalangeal fractures. *J Hand Surg* 9A:725, 1984
5. Bosscha K, Snellen JP: Internal fixation of metacarpal and phalangeal fractures with AO minifragment screws and plates: A prospective study. *Injury* 24:166, 1993
6. Botte MJ, Davis JL, Rose BA, et al: Complications of smooth pin fixation of fractures and dislocations in the hand and wrist. *Clin Orthop* 276:194, 1992
7. Crawford G: Screw fixation for certain fractures of the phalanges and metacarpals. *J Bone Joint Surg* 58A:487, 1976
8. Crofoot CD, Saing M, Raphael J: Intrafocal pinning for juxtaarticular phalanx fractures. *Tech Hand Upper Extrem Surg* 9:164, 2005
9. Dabezies EJ, Schutte JP: Fixation of metacarpal and phalangeal fractures with miniature plates and screws. *J Hand Surg* 11:283, 1986
10. Diwaker HN, Stothard J: The role of internal fixation in closed fractures of the proximal phalanges and metacarpals in adults. *J Hand Surg* 11B:103, 1986
11. Drenth DJ, Klasen HJ: External fixation for phalangeal and metacarpal fractures. *J Bone Joint Surg* 80B:227, 1998
12. Duncan RW, Freeland AE, Jabaley ME, Meydrech EF: Open hand fractures: an analysis of the recovery of active motion and of complications. *J Hand Surg* 18A:387, 1993
13. Feehan L, Sheps S: Incidence and Demographics of Hand Fractures in British Columbia, Canada: A Population-Based Study. *J Hand Surg* 31(7):1068, 2006
14. Fitoussi F, Lu W, Ip W, Chow S: Biomechanical properties of absorbable implants in finger fractures. *J Hand Surg* 23B:79, 1998
15. Flatt AE: Closed and open fractures of the hand: Fundamentals of management. *Postgrad Med* 39:17, 1996
16. Freeland AE, Jabaley ME, Burkhalter WE, Chaves AM: Delayed primary bone grafting in the hand and wrist after traumatic bone loss. *J Hand Surg* 9:22, 1984
17. Freeland AE: *Hand Fractures: repair, reconstruction, and rehabilitation*. 1st ed. Churchill Livingstone, Philadelphia, 2000.
18. Gonzalez MH, Hall Jr RF: Intramedullary fixation of metacarpal and proximal phalangeal fractures of the hand. *Clin Orthop* 327:47, 1996

19. Green DP, Anderson JR: Closed reduction and percutaneous pin fixation of fractured phalanges. *J Bone Joint Surg* 55A:1651, 1973
20. Gutow A, Slade J, Mahoney J: Hand Fractures and Joint Injuries. p. 3. In Trumble TE (ed.) *Hand Surgery Update 3: Hand Elbow and Shoulder*. Amer Soc Surgery of the Hand, Rosemont, IL, 2003
21. Halliwell PJ: The use of external fixators for finger injuries: pin placement and tethering of the extensor hood. *J Bone Joint Surg* 80B:1020, 1998
22. Hastings II H: Unstable metacarpal and phalangeal fracture treatment with screws and plates. *Clin Orthop* 214:37, 1987
23. Hornbach EE, Cohen MS: Closed reduction and percutaneous pinning of fractures of the proximal phalanx. *J Hand Surg* 26B:45, 2001
24. Horton TC, Hatton M, Davis TR: A prospective randomized controlled study of fixation of long oblique and spiral shaft fractures of the proximal phalanx: closed reduction and percutaneous Kirschner wiring versus open reduction and lag screw fixation. *J Hand Surg* 28B:5, 2003
25. Kawamura K, Chung KC: Fixation choices for closed simple unstable oblique phalangeal and metacarpal fractures. *Hand Clin* 22:287, 2006
26. Kozin S, Thoder J, Lieberman G: Operative treatment of metacarpal and phalangeal shaft fractures. *J Am Acad Orthop Surg* 8:111, 2000
27. Kurzen P, Fusetti C, Bonaccio M, Nagy L: Complications after plate fixation of phalangeal fractures. *J Trauma* 60:841, 2006
28. Lins RE, Myers BS, Spinner RJ, Levin LS: A comparative mechanical analysis of plate fixation in a proximal phalangeal fracture model. *J Hand Surg* 21A:1059, 1996
29. Lu W, Furumachi K, WY I, Chow S: Fixation for comminuted phalangeal fractures. A biomechanical study of five methods. *J Hand Surg* 21B:765, 1996
30. Margic K: External fixation of closed metacarpal and phalangeal fractures of digits. A prospective study of one hundred consecutive patients. *J Hand Surg* 31B:30, 2006
31. Matloub HS, Jensen PL, Sanger JR, Grunert BK, Yousif NJ: Spiral fracture fixation techniques. A biomechanical study. *J Hand Surg* 18B:515, 1993
32. Nunley JA, Kloen P: Biomechanical and functional testing of plate fixation devices for proximal phalangeal fractures. *J Hand Surg* 16A:991, 1991
33. Orbay JL, Touhami A: The treatment of unstable metacarpal and phalangeal shaft fractures with flexible nonlocking and locking intramedullary nails. *Hand Clin* 22:279, 2006
34. Ouellette EA, Dennis JJ, Latta LL, Milne EL, Makowski AL: The role of soft tissues in plate fixation of proximal phalanx fractures. *Clin Orthop* 418:213, 2004
35. Page S, Stern P: Complications and range of motion following plate fixation of metacarpal and phalangeal fractures. *J Hand Surg* 23:827, 1998

36. Papadonikolakis A, Li Z, Smith BP, Koman LA: Fractures of the phalanges and interphalangeal joints in children. *Hand Clin* 22:11, 2006
37. Roser S, Gellman H: Comparison of nailbed repair versus nail trephination for subungual hematomas in children. *J Hand Surg* 24(6):1166, 1999
38. Schatzker J: Screws and plates and their application. p. 179. In Muller ME, Allgower M, Schneider R, Willenegger H (eds): *Manual of Internal Fixation: Techniques Recommended by the AO-ASIF Group*. 3rd ed. Springer-Verlag, New York, 1991
39. Seymour N: Juxta-epiphysial fracture of the terminal phalanx of the finger. *J Bone Joint Surg* 48B:347, 1966
40. Simon RR, Wolgin M: Subungual hematoma: association with occult laceration requiring repair. *Am J Emerg Med* 5:302, 1987
41. Smith RJ: Balance and kinetics of the fingers under normal and pathological conditions. *Clin Orthop* 104:92, 1974
42. Swanson T, Szabo R, Anderson D: Open hand fractures: prognosis and classification. *J Hand Surg* 16A:101, 1991
43. Tencer AF, Johnson KD, Kyle RF, Fu FH: Biomechanics of fractures and fracture fixation. *Instr Course Lect* 42:19, 1993
44. Vahey J, Wegener D, Hastings H: Effect of proximal phalangeal fracture deformity on extensor tendon dysfunction. *J Hand Surg* 23:673, 1998
45. Viegas SF, Ferren EL, Self J, Tencer AF: Comparative mechanical properties of various Kirschner wire configurations in transverse and oblique phalangeal fractures. *J Hand Surg* 13:246, 1988
46. Trigg, S. Fractures of the Metacarpals and Phalanges. AAHS Review 2005