



Early Outcomes of Pyrolytic Carbon Proximal Interplangeal Joint Arthroplasty Using the Lateral Approach

Pacelli L, Martin M, Kivirahk D, Myerson A, Botte M
 Division of Orthopaedic Surgery, Scripps Clinic, La Jolla, Ca.

Disclosure:

Consultant agreement Ascension Orthopedics
 No funding provided for this study

Study:

Many clinical results have been reported for PIP arthroplasty using both the dorsal and the lateral approach. The lateral approach has gained recent popularity as it avoids postoperative extensor tendon imbalance complications seen in the dorsal approach. This study reports on early prospective outcomes data on pyrolytic carbon PIP arthroplasty (PCA) using the lateral approach.

Methods:

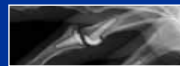26 Primary PCA PIP (ascension orthopedics)
 All performed via Lateral Approach
 19 patients (14 females, 5 males)
 Mean age 61 (range 24 – 83)
 Mean followup 13.2 months
 Outcomes measurements:

- Patient satisfaction
- Disability
- Pain
- DASH scores
- Range of motion
- Grip and pinch strength
- Radiography

Surgery from any complication considered as a failure

Complications: (2 implants)

- One with subsidence requiring revision
- One with ankylosis requiring caspulectomy/release
- NO implant developed collateral instability or squeaking

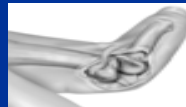

Surgical Technique:

Lateral Approach as described by V. Mazzone, M. Ceruso, Italy and R. Beckenbaugh, Rochester

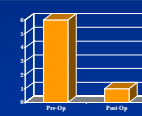
Modified Lateral Approach to the PIP.

Z Incision of the ulnar collateral ligament



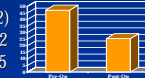
Pain (VAS):

Lateral:
 Pre-Op: 6
 Post-Op: 1



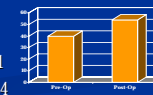
Dash Scores:

Lateral: (p 0.002)
 Pre-Op: 47.12
 Post-Op: 25.65



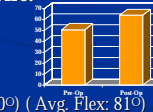
Grip (lbs):

Lateral: (p 0.04)
 Pre-Op: 39.81
 Post-Op: 53.94



Active ROM Arc:

Lateral: (p 0.07)
 Pre-Op: 51°
 Post-Op: 64°
 (range 28° – 110°) (Avg. Flex: 81°)



Lateral Pinch: (p 0.04)

Pre-OP: 12.95
 Post-OP: 16.16

3-point Pinch: (p 0.001)

Pre-OP: 10
 Post-OP: 15

Summary Points

To our knowledge, this is the first study to present early functional and clinical outcomes using the lateral surgical approach for Pyrolytic Carbon PIP arthroplasty. The lateral approach avoids the extensor mechanisms and associated soft tissue imbalance reducing the risk of hyperextension deformity seen with the dorsal approach. The lateral approach demonstrated better clinical outcomes and fewer complications than the dorsal approach.