

Arthroscopic Assessment of the Wrist in Kienböck's Disease

Marcelo Rosa de Rezende , Emygdio Leomil de Paula, Rames Mattar Junior, Edgar França Bisneto
Hand and Microsurgery Division of Orthopaedic Institute of University of São Paulo, Brazil

Introduction

Some findings reinforce the concept that there is a discrepancy between radiological staging and the clinical evolution of the patient in Kienböck's disease. We believe that there are other changes, not visible upon radiographic examination, which may contribute to patient's clinical condition.

Goal

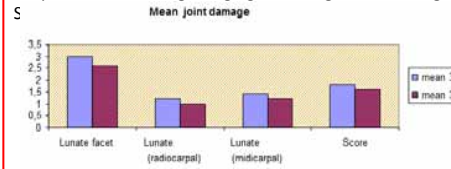
Evaluation of arthroscopic findings in patients classified as stage 3 A and 3 B, according Lichtman Classification

Material and Method

- 15 patients, Kienböck stage 3 (Lichtmann's Classification)
- 5 Stage 3 A and 10 stage 3 B, according radiological findings.
- Arthroscopic staging using portal 3 and 4 and Outerbridge Classification

Result

Graphic 1 - Joint Damage Staging according to Outerbridge S



Result

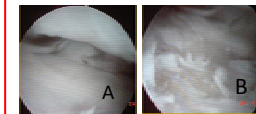


Fig.1-Scaphoid groove, without chondral damage(A).Lunate groove exhibiting type 2 chondral damage (B)

Result

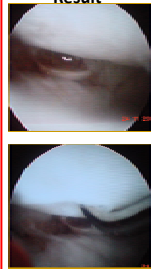
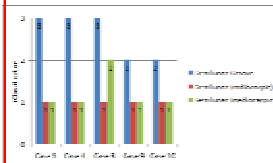


Fig 2-Views of Lunate presenting type 2 chondral lesion

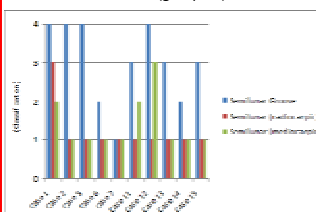
Result

Graphic 2-Degree of articular damage at specific sites, using the Outerbridge classification scheme - Group 3A



Result

Graphic 3-Degree of articular damage at specific sites, using the Outerbridge classification scheme (group 3B)



Result

- Same pattern of damaging for 3A and 3B.
- Lunate fossa damaged in all cases.
- Lunate damaged to varying degrees.
- Preservation of scaphoid fossa and capitate in all cases.
- Capitate preserved in all cases.

Discussion

In our study of 15 patients with stage 3A or 3B Kienböck's disease, we sought to objectively evaluate the articular state of the wrist. What we found was wide variations in the degree of articular compromise, in patients with stage 3, as classified by Lichtman. These facts favor the use of arthroscopy for correct articular staging of the wrist in patients with Kienböck's disease, thereby providing additional data by which to select the best surgical procedure.

Conclusion

Wrist arthroscopy showed to be a good tool to evaluate the articular status of patient with Kienböck's disease

